

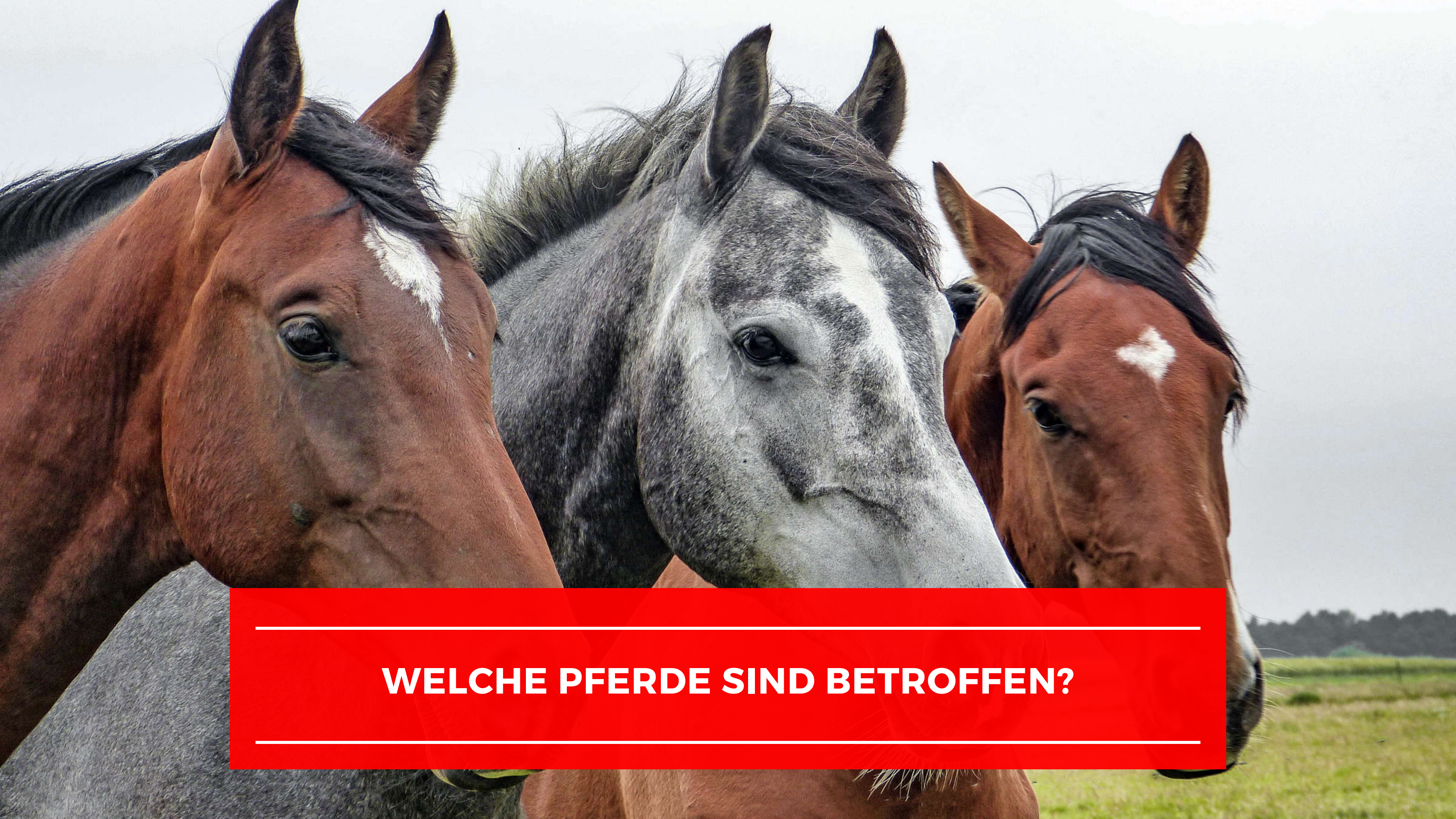
WEBINAR-WOCHE 2021

# KREBS NATURHEILKUNDLICH BEGLEITEN

Thema heute: Melanome und Sarkoide bei Pferden



REFERENTIN  
FRANZISKA WOJEWSKI

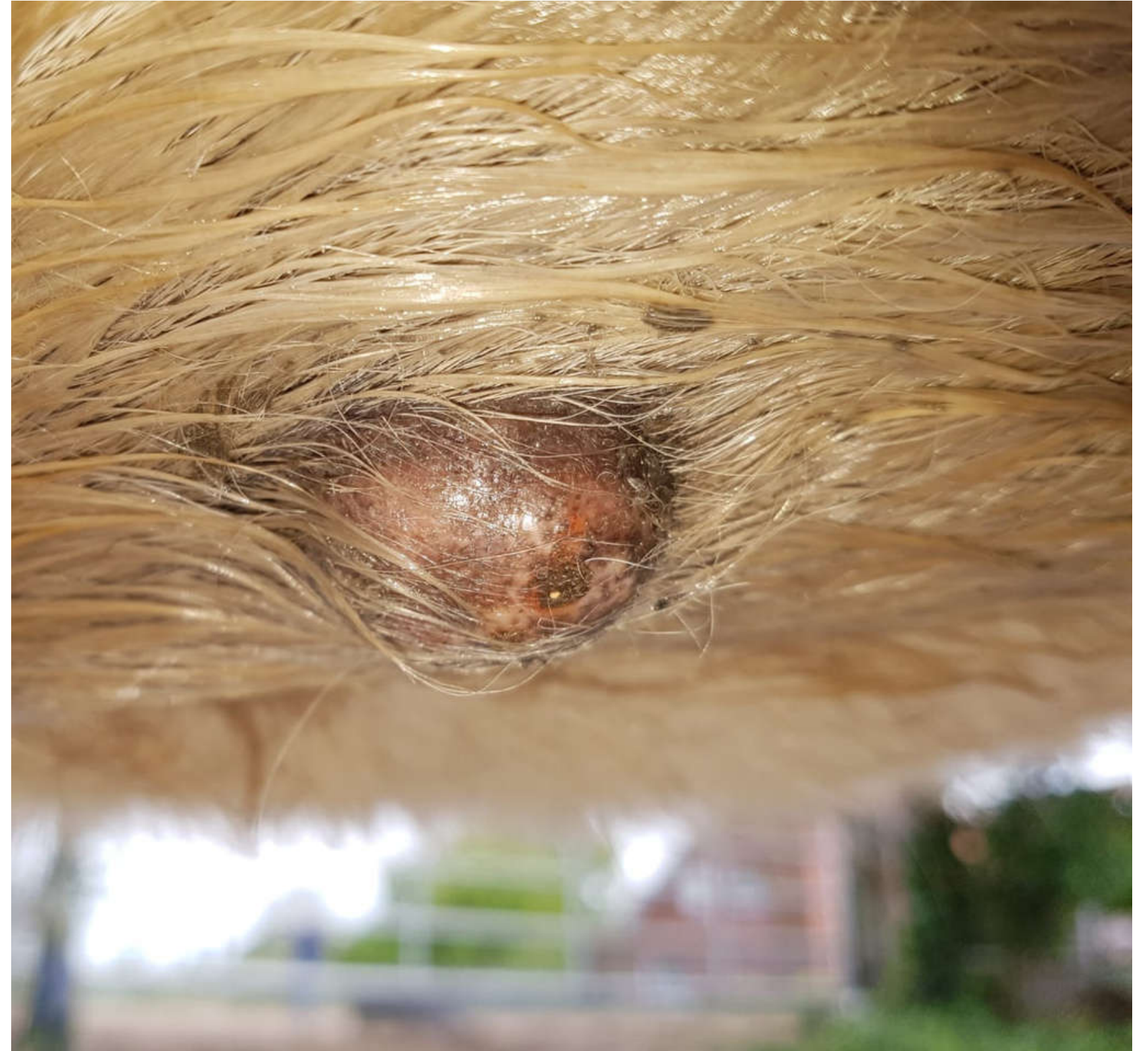

---

**WELCHE PFERDE SIND BETROFFEN?**

---

**WAS SIND EQUINE  
SARKOIDE?**



# WELCHE ARTEN VON SARKOIDEN SIND BEKANNT?



OKKULTE  
SARKOIDE

VERRUKÖSE  
SARKOIDE

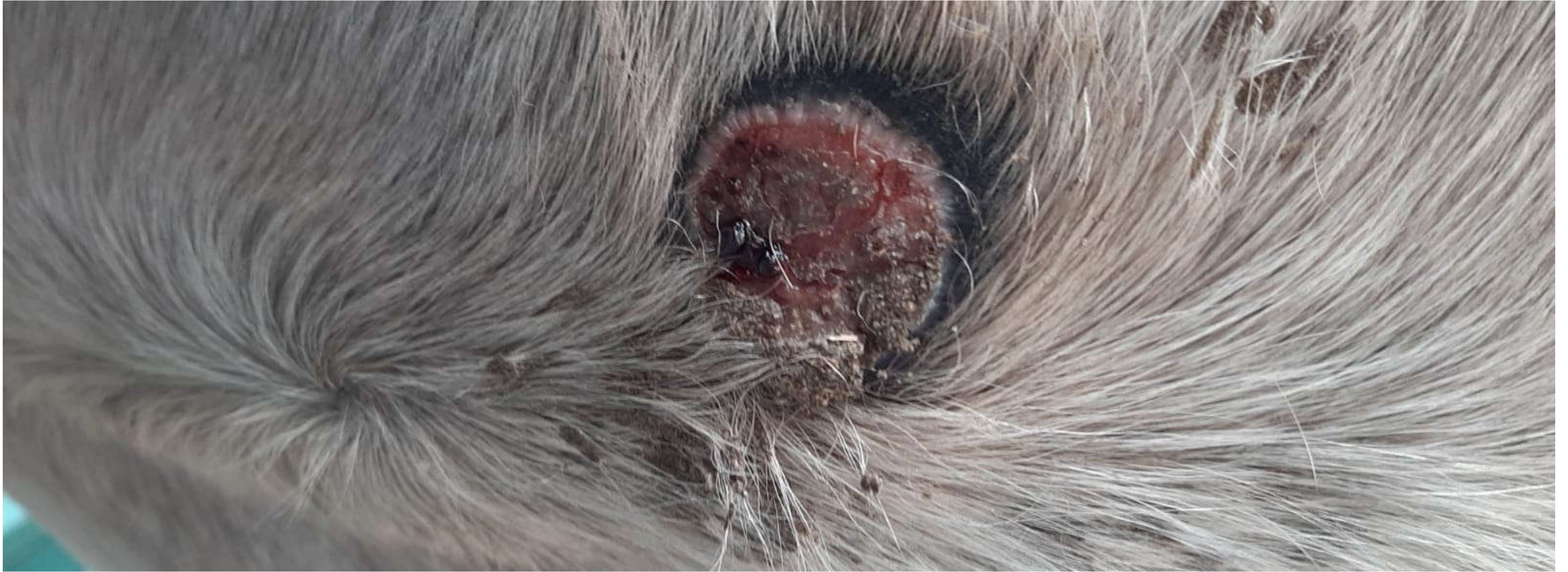NODULÄRE  
SARKOIDE

FIBROBLASTISCHE  
SARKOIDE

MALEVOLENTE  
SARKOIDE

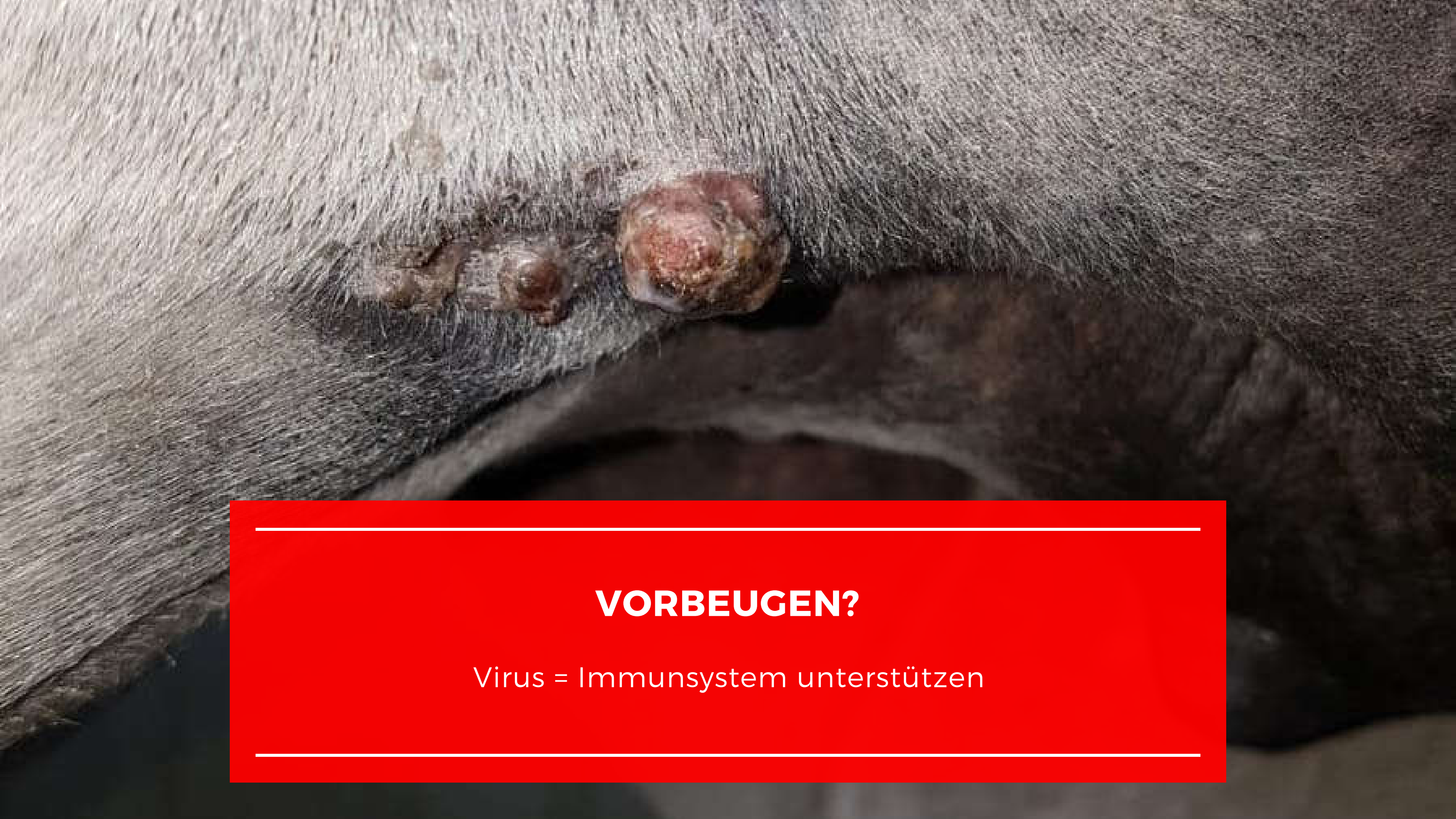
GEMISCHTE  
SARKOIDE

---



# MÖGLICHE URSACHEN FÜR SARKOIDE

---

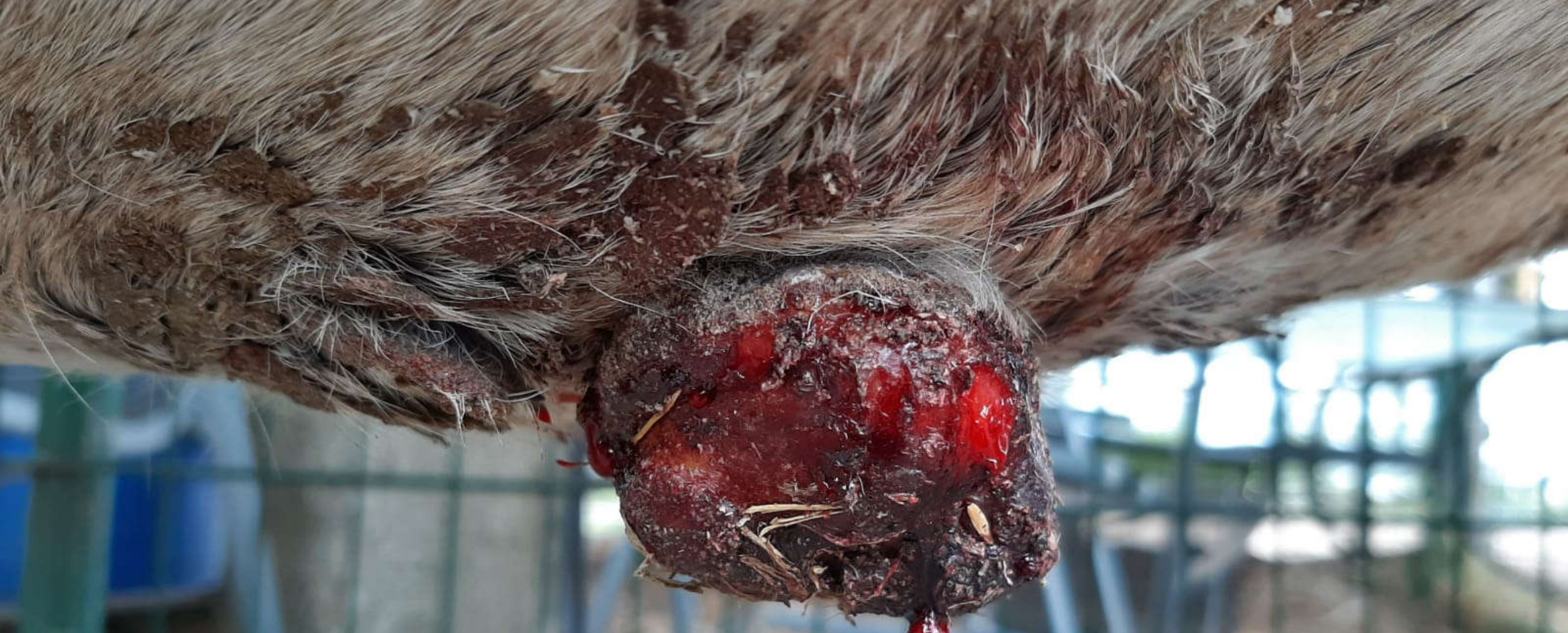

---

## **VORBEUGEN?**

Virus = Immunsystem unterstützen

---

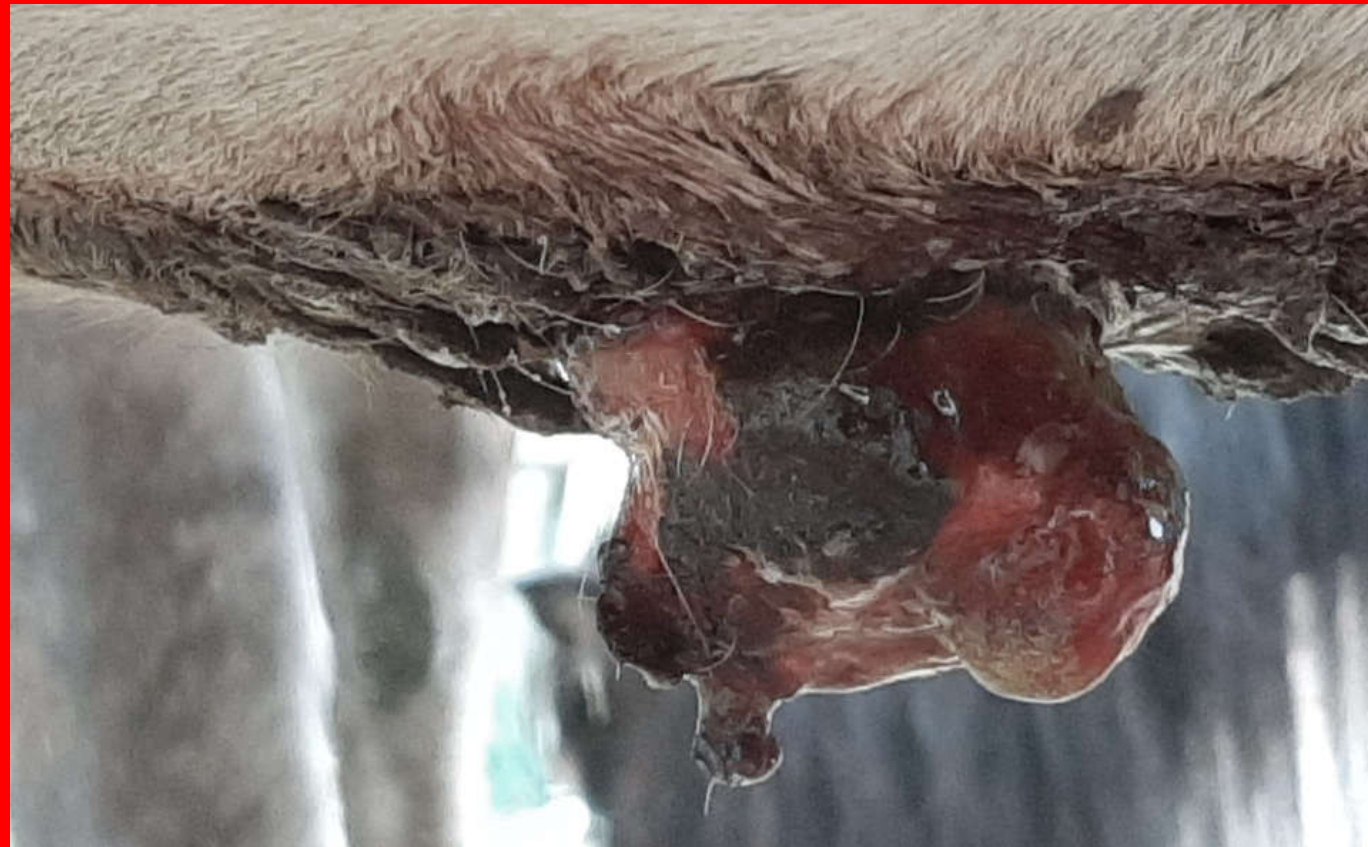

---

**DIAGNOSE**

---

# BEHANDLUNG

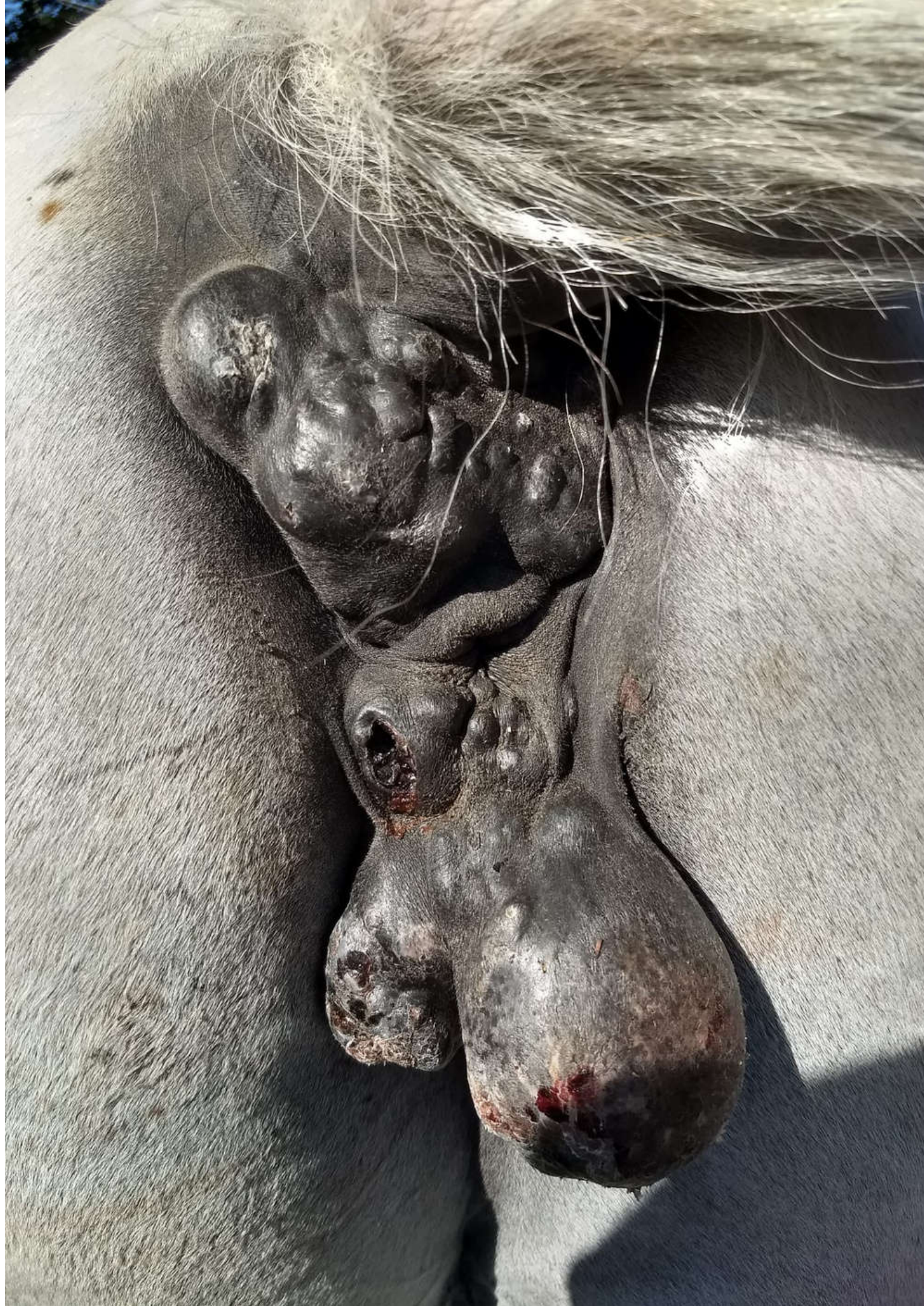

- Futter
- Homöopathie
- Immuntherapie
- Abfrieren
- Abbinden
- Salben
- Impfung
- Injektion
- Bestrahlung



A close-up photograph of a black dog's head, possibly a Labrador Retriever, resting against a red brick wall. The dog's face is the primary focus, with a dark, irregularly shaped spot visible on its snout. The background consists of a standard red brick wall with visible mortar lines. A red rectangular box with white horizontal lines is overlaid at the bottom of the image, containing the word 'MELANOME' in white, bold, uppercase letters.

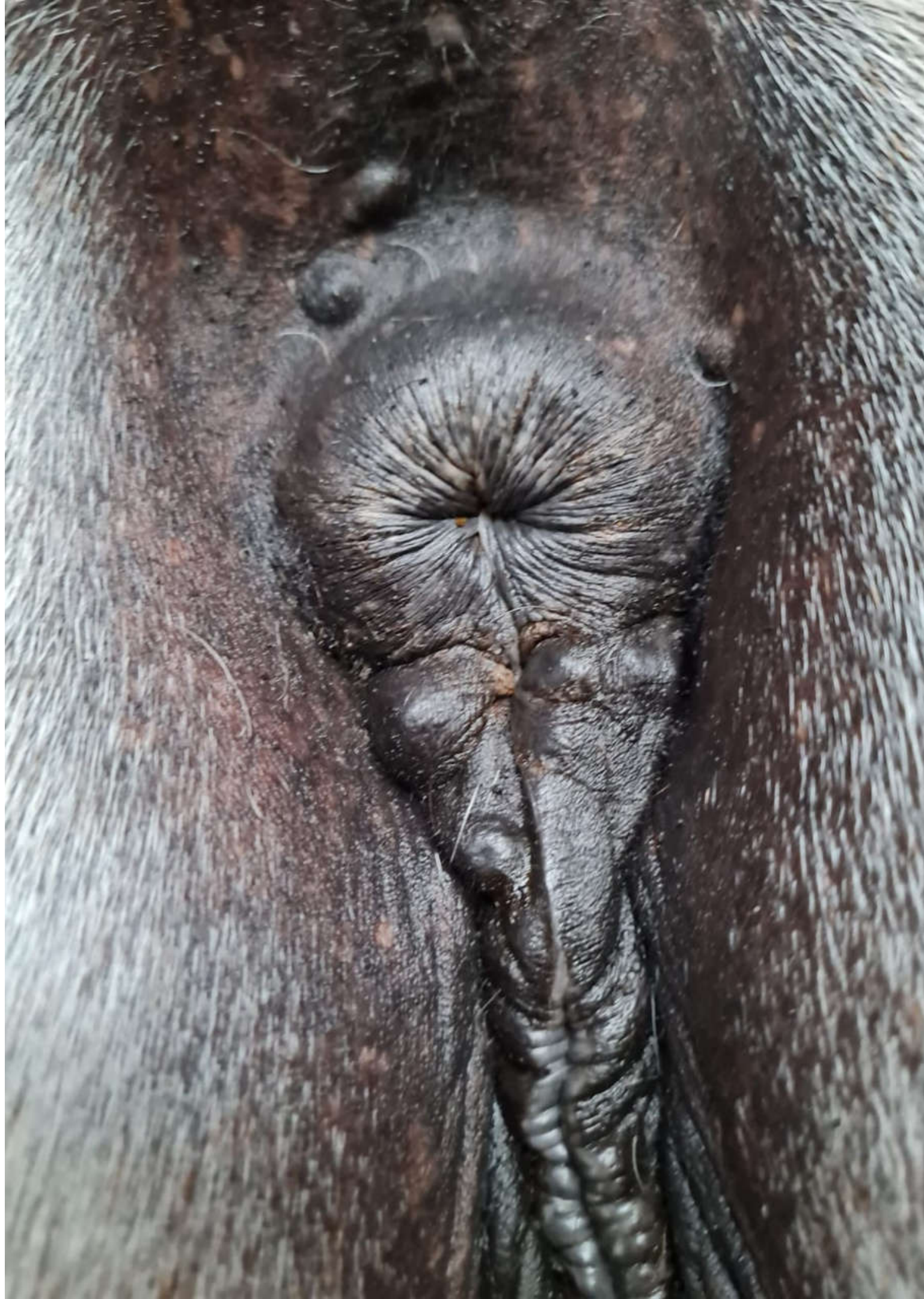**MELANOME**



---

**URSACHEN**

---

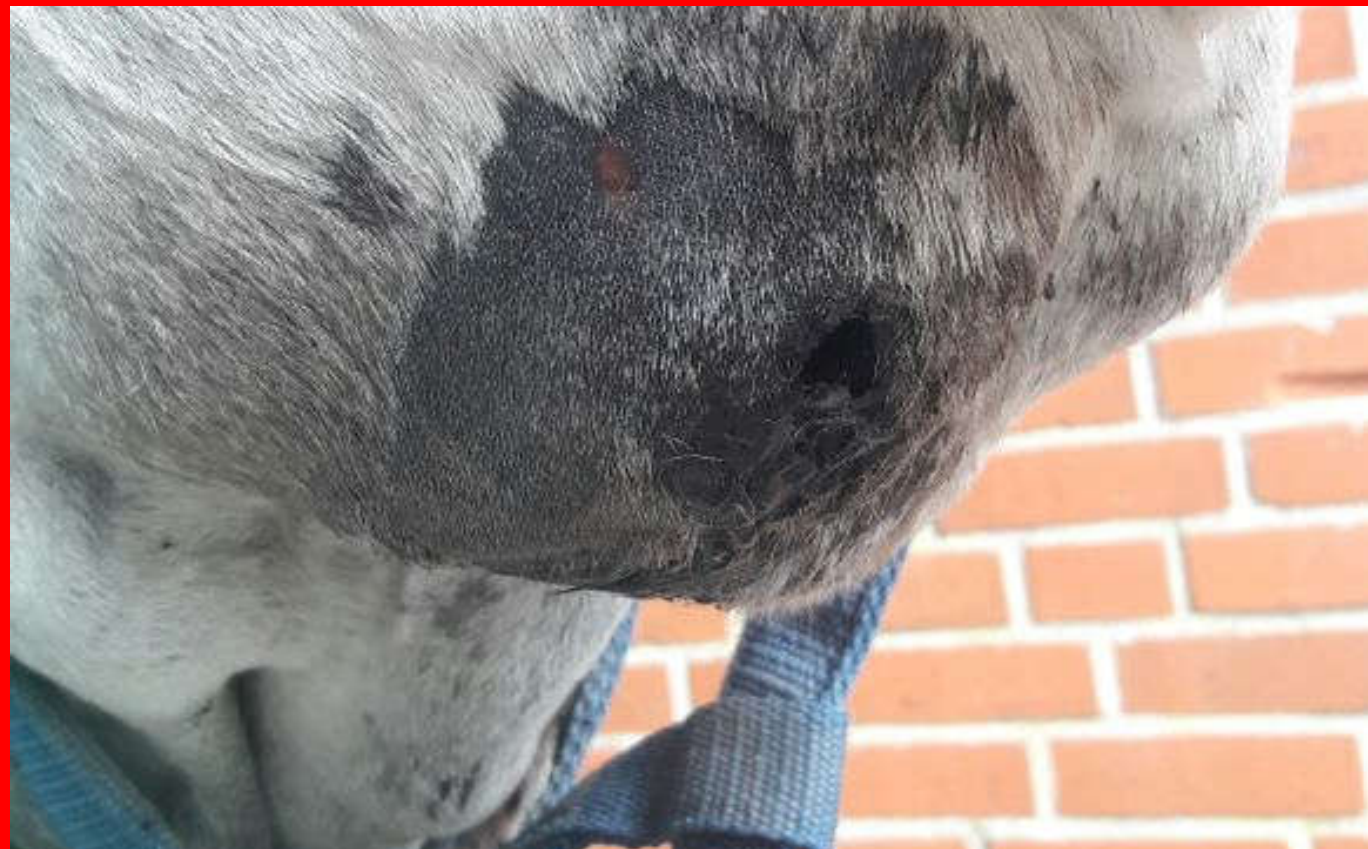

---

**DIAGNOSE**

---

# BEHANDLUNG



- Chirurgische Eingriffe
- Chemotherapie
- Immunotherapie
- Homöopathie
- Phyto

A close-up photograph of a horse's eye. The eye is dark and appears to have a small, dark, circular lesion or opacity on the cornea. The surrounding area is covered in light-colored, coarse hair. A person's hand is visible on the left side, holding the horse's head.

## **VORBEUGEN?**

Fast nicht möglich durch die genetische Komponente



# FRAGEN?

FRANZISKA WOJEWSKI

Dozentin der Tierheilpraxis & Naturheilschule Prester

TIERHEILPRAXIS PRESTER

[www.thp-prester.de](http://www.thp-prester.de)

[info@thp-prester.de](mailto:info@thp-prester.de)

---